

CASE STUDY

Improvement in Sleep and Quality of Life in a Child with Cerebral Palsy Undergoing Chiropractic Care

Lori Goodsell, B.S., D.C.¹ & Jennifer Schneider, B.S.²

Abstract

Objective: To report on a female patient with cerebral palsy who presented for chiropractic care.

Clinical Features: Sixteen year old female with a history of cerebral palsy and findings of vertebral subluxation resulting in poor sleep habits and muscle spasticity. She was non-ambulatory, uncommunicative and non-responsive, and due to these complications she had been fed through a feeding tube and had a complete liquid diet since birth.

Interventions and Outcomes: Over a period of six months, a specific, conservative chiropractic adjustment regimen for the correction of vertebral subluxation was administered to the patient, explicitly the motion palpation technique utilizing a specific seated cervical adjustment. The patient exhibited a considerable decrease in sleep disturbance. Static surface EMG and thermal scanning were performed using the Insight® surface EMG and thermal scanning technology. Improvements were noted in surface EMG scanning over the six months of care and thermal scanning revealed a dynamic pattern.

Conclusion: While under chiropractic care, subjective and objective improvements resulting in physical changes for the patient and quality of life improvements within her family were documented in a patient with cerebral palsy and sleep disturbances.

Key Words: *chiropractic, vertebral subluxation, quality of life, cerebral palsy, sleep disturbance, surface EMG, thermography*

Introduction

Cerebral palsy is a disease process that does not have a specific known cause or etiology. It is described as a non-progressive motor impairment syndrome from lesions and/or anomalies of the brain and central nervous system, typically caused by birth trauma. Due to such a broad, vague definition of cerebral palsy, it is not easily diagnosed before the age of

two.^{1,2} According to the National Institute of Neurological Diseases and Stroke, 4,500 new cases are diagnosed in the United States every year.³ It is also estimated that 2.5 out of every 100,000 kids are diagnosed with cerebral palsy.^{1,4,5}

Another description of cerebral palsy is a disorder of the brain where it has failed to develop properly or has been damaged. Either can cause impairment to the motor areas of the brain resulting in the inability to control movement or posture. Cerebral palsy can range from very mild, manageable cases to a severe, debilitating disease where the individual has extreme cognitive, emotional, and physical dysfunction. There are multiple forms of cerebral palsy, with the most common being

1. Private Practice of Chiropractic, Plymouth, MN, USA
2. Student Intern, Life University College of Chiropractic, Marietta, GA, USA

spastic cerebral palsy affecting 70-80% of individuals diagnosed with cerebral palsy.^{6,7} Other types include: dyskinetic, ataxic, and atonic.⁴ In addition, anatomical involvement can be monoplegia, diplegia, hemiplegia, triplegia, or quadriplegia.⁸

Delgado et al stated that spasticity is, “*Hypertonia in which one or both of the following signs are present: 1) resistance to externally imposed movement increases with increasing speed of stretch and varies with the direction of joint movement; 2) resistance to externally imposed movement rises rapidly above a threshold speed of joint angle.*”⁹ Common complaints arising from spastic cerebral palsy are muscle spasticity and difficult ambulation. These jerky movements are characteristically caused by lesions to the pyramidal and extra pyramidal pathways.¹⁰

Most people diagnosed with cerebral palsy have no related noetic disadvantages or medical disorders. However, in more severe cases, it is associated with cognitive impairment, reduced intellectual capacity and development, inattentiveness to the outside world, growth deficiency, impaired vision and or hearing, abnormal sensation and perception, sleep disturbances and seizures.^{6,7} It has also been noted that those diagnosed with cerebral palsy are more likely to have comorbidities such as bladder and bowel problems such as constipation. This is often a result of insufficient nutrition which could be caused by absorption problems.⁵

There are a variety of risk factors that may cause cerebral palsy. These include: premature births, infants suffering from hypoxic – ischemic encephalopathy, infants that endure seizures and those children who have had cortical artery infarct.¹ Although there are many other risk factors to take into account, the above mentioned are the most common.^{1,4,11}

Further, cerebral palsy is diagnosed in 8 - 10% of children born with low birth weight, typically occurring in children born premature. To be considered in the very low birth weight category, the child has to weigh less than 1000 grams. Many times they have problems with visual impairments, growth disorders, and respiratory problems. In the premature child and those born with very low birth weights, the most common type of cerebral palsy is diplegic.²

Classification

The Gross Motor Function Classification System (GMFCS) considers five different levels. Level One is the most minor and includes children who can walk and perform all activities that others in their same age range can do. However, there are limitations in speed, balance, and coordination. Level Two indicates the person can walk without assistance but is limited in advanced walking. Level Three implies they require a walking device, while Level Four suggests that they need someone else to transport them. Level Five, the most serious, includes those who cannot travel on their own. Individuals at this level have problems with trunk motion and almost no control over any other extremity movement.¹²

Case Report

Patient History

A 16 year old patient with cerebral palsy presented to the office for the correction of vertebral subluxation. She had been born three months premature, weighing only four pounds and six ounces. She had multiple congenital anomalies, including a neural tube defect and a trachea-esophageal fistula. Soon after birth, she had a right ventricular shunt placed in her heart. Then, at the age of seven, she had Harrington rods placed in her spine to fuse it from T2- sacrum. The patient was diagnosed with pneumonia and respiratory syncytial virus (RSV) on three separate occasions.

She was confined to a wheel chair and was severely physically and cognitively impaired. She was non-ambulatory, uncommunicative, and non-responsive. Due to these complications, she had been fed through a feeding tube and had a complete liquid diet since birth. She had inconsistent vocal outbursts of a screeching nature. Further, she exhibited continual writhing of her cervical spine. Her gross motor coordination was limited to sporadic reaching out with her hands.

The patient’s mother was aware of the benefits of chiropractic care and how it could reduce muscle spasticity and sleep disturbances associated with cerebral palsy. The patient would typically sleep from around 10 pm and then wake up at 3 or 4 am daily, which the mother attributed to uncontrollable leg movements similar to those associated with restless leg syndrome. The patient would also wake up at several other times throughout the night. After waking up at approximately 3 or 4 am, the teenager required constant attention for the remainder of the day. As a result, sleep deprivation was causing turmoil and affecting family dynamics.

Examination

The patient was difficult to examine as a result of her spasticity and inability to ambulate or stand without assistance. Initial examination with sEMG and thermal scanning technology revealed severely increased neural output in the upper cervical and thoracic region spine and abnormally decreased neural output in the thoracolumbar region of the spine. (Figures 1 & 2) Upon visual examination and palpation, the child was found to be subluxated at C1 and C7.

Due to the patient’s condition, routine postural evaluation or radiographic mensuration was not performed as they would not accurately be able to detect subluxation due to the patient’s constant motion. The examiner used the Insight Millennium Subluxation Station® to assess neurological function by performing thermography and sEMG evaluations. (Figures 1-7)

The thermal scans performed did not show a reduction dysautonomia throughout the course of care but the pattern was dynamic. The patient was found to have +3 hypertonic muscles throughout the upper cervical spine indicating aberrant neural output as well as +3 hypertonic muscles in the upper thoracic spine. It is suspected that due to the Harrington rods placed throughout her thoracic and lumbar spine, the

neural output had been altered such that her muscles were hypotonic between T8-L3.

Intervention

The patient began her adjustments one week after her exam at a two adjustment per week frequency. The examiner was initially concerned because the patient was not completely capable of providing subjective findings. In addition, it was unknown whether she had the cognition to understand what was happening to her. Since the patient had been subject to many medical procedures in the past that were very frightening to her, the decision was made to begin slowly and ease her into the process of chiropractic adjustments.

The examiner feared the patient would resist future adjustments if she was aggressively adjusted on the first visit. Therefore, during the first visit, the doctor used light mobilization of the neck to allow the patient to familiarize herself with the doctor's touch. After a few visits, the doctor began moving her neck gently in a rotary and lateral bending fashion to allow the patient to become comfortable with the motions used for the adjustments. Upon the patient becoming more familiar with the doctor, light thrusts were executed, followed by more forceful adjustments to obtain an audible.

On several occasions the patient's lack of cooperation prohibited a manual adjustment, so the doctor had to use an Activator or a lighter thrust. Other days, the patient's muscle spasticity prohibited the range of motion.

Outcome

During the second visit the doctor was able to apply two manual adjustments lightly that did not result in an audible release. On her sixth adjustment, the patient's mother reported that she was sleeping normally and uninterrupted throughout the night. Subsequently, at the ninth visit, the patient had a sEMG and thermography scan repeated and improvements were observed in the sEMG readings. (Figure 7) Only mild muscle tone asymmetry was noted on the last scan. Throughout the course of care there was a decrease in number of fixations which is believed to be associated with the reduction of sleeping disturbances. The patient was able to sleep for longer hours without waking throughout the night.

Discussion

Chiropractic care is frequently utilized by parents interested in a complementary health approach as a proactive choice compared to traditional disease care. Multiple case studies have been published citing improvement in the quality of life of children with special needs. Due to reduction of subluxation, multiple reports have been cited of better quality sleep patterns, resolution of strabismus, decreased spasticity, and resolution of grand mal seizures, normalized pupillary reflex and improved vocalization.^{13, 14}

Many chiropractors make use of some type of instrumentation to show patients' progress while they are under care. Several chiropractors utilize instrumentation in their practices due to the fact it offers not only an objective measure of patient outcome, but also serves as a visual aid to illustrate their

progression.

One specific type of instrumentation is thermal scanning. Thermal scans are used along the length of the spine to measure paraspinal cutaneous temperature differentials from one side of the spine to the other.¹⁵ This particular technique has been used since 1924.¹⁶ An additional form of instrumentation is surface electromyography (sEMG), which is utilized to record the amount of muscle tension measured through the electrical activity of the musculature.¹⁷

In a case study described by Valente, a 2 year old African American boy with cerebral palsy showed improved sleeping behaviors as well as walking ability due to chiropractic care. His feeding schedule went from 3 times per night to only 1 time and he was able to make eye contact for a longer period of time. This particular evaluation utilized diversified technique and cranial work as treatment for the patient.¹⁸

A retrospective case study of four patients with cerebral palsy was done to demonstrate that the reduction of vertebral subluxation resulted in improvements in their quality of life. The four patients included: two girls ages 8 and 10, and two boys ages 7 and 12, who presented with a variety of symptoms associated with cerebral palsy such as sleeping disturbances, extremity tremors, seizures, poor posture and mobility, issues with balance, concentration in school, depression, and multiple others. After only 12 adjustments over four weeks of care each patient saw a reduction in at least three or more of their symptoms.⁴

A possible explanation for the improvements experienced by the patient could be a result of the indirect effects the adjustment had on the brain through the afferent inputs from the proprioceptive and nociceptive structures associated with the vertebral joint complex. It is plausible when an adjustment is received that it may affect the neurology of the disc, muscle spindles and Golgi Tendon Organs of the paraspinal musculature, and proprioceptors in the facet capsule. These low threshold receptors, along with the many nociceptive fibers found throughout the vertebral motion unit, contribute input via spinal and brainstem tracts to various CNS sites including the cerebellum, thalamus, cerebral cortex and, the hypothalamus.¹⁹

It is theorized that as a result of chiropractic adjustments the pituitary gland, endocrine system, and vascular system are better able to communicate with the brain, thus changing the output of the brain through better communication with the limbic cortex, intermediate lateral columns, and pre and post ganglionic sympathetic efferents.¹⁹

In a review of the models of vertebral subluxation, Kent described the nerve root compression model, which also supports a mechanism for improvement. In the model, it states that only 10mm Hg of pressure is required to have an effect on the nerve impulse transmission of a spinal nerve root. A 60% reduction in nerve conduction was noted after only 15 minutes of 10mm Hg was applied. In addition, total recovery was distinguished with removal of the pressure 15 to 30 minutes later.¹⁹ Therefore, it should be understood that proper spinal alignment and motion is necessary for optimal interaction between the brain and the rest of the body. It is

also important to mention that only two of the nine adjustments administered to the patient, in this case, generated an audible release, indicating it is not necessary for an audible to be heard for neural output to improve.

Conclusion

In the above referenced case regarding the patient with severe cerebral palsy, electromyographic findings indicated improvement in muscle tone and there was a decrease in fixation at C1 as a result of regular chiropractic adjustments. Upon improvement of the vertebral subluxations, the patient and her family were able to return to a normal sleep schedule as well as enjoy improved quality of life.

Acknowledgment

"Special thanks to Dr. Mary Tuchscherer of North Western Health Sciences University for her assistance reviewing drafts of this paper."

References

1. Wood E. The child with cerebral palsy: diagnosis and beyond. *Semin Pediatr Neurol*. 2006 Sept;13:286-296.
2. Marlow N. Neurocognitive outcome after very preterm birth. *Arch Dis Child Fetal Neonatal Ed*. 2004 May;89(3):F224-8.
3. National Institute of Neurological Disorders and Stroke Informational Website Regarding Cerebral Palsy.
4. McCoy M, Malakhova E, Safronov Y, Kent C, Scire P. Improvement in paraspinal muscle tone, autonomic function and quality of life in four children with cerebral palsy undergoing subluxation-based chiropractic care: four retrospective case studies and review of literature. *J Vert Sublux Res*. 2006 Jun 21;1-15.
5. Tarsuslu T, Bol H, Simsek IE, Toylan IE, Cam S. The effects of osteopathic treatment on constipation in children with cerebral palsy: a pilot study. *J Manipulative Physiol Ther*. 2009 Oct;32(8):648-53.
6. Kotagal S, Gibbons VP, Stith JA. "Sleep Abnormalities in Patients with Severe Cerebral Palsy", *Dev Med Child Neurol* 1994 Apr;36(4):304-11.
7. Hayashi M, Inoue Y, Iwakawa Y, Sasaki H., "REM Sleep Abnormalities in Severe Athetoid Cerebral Palsy", *Brain Dev* 1990;12(5):494-7.
8. I Tsirikos A. Development and treatment of spinal deformity in patients with cerebral palsy. *Indian J Orthop*. 2010 Apr;44(2):148-58.
9. Delgado MR, Hirtz D, Aisen M, Ashwal S, Fehlings DL, McLaughlin J, Morrison LA, Shrader MW, Tilton A, Vargus-Adams J. Practice parameter: pharmacologic treatment of spasticity in children and adolescents with cerebral palsy. *Neurology*. 2010 Jan 26;74(4):336-43.
10. Elbasiouny SM, Moroz D, Bakr MM, Mushahwar VK. Management of spasticity after spinal cord injury: current techniques and future directions. *Neurorehabil Neural Repair*. 2010 Jan;24(1):23-33.
11. Hvidtjorn D, Schieve L, Schendel D, Jacobsson B, Svaerke C, Thorsen P. Cerebral palsy, autism spectrum disorders, and developmental delay in children born after assisted conception: a systematic review and meta-analysis. *Arch Pediatr Adolesc Med*. 2009 Jan;163(1):72-83.
12. Ghasia F, Brunstrom J, Gordon M, Tyachsen L. Frequency and severity of visual sensory and motor deficits in children with cerebral palsy: gross motor function classification scale. *Invest Ophthalmol Vis Sci*. 2008 Feb;49(2):572-80.
13. Collins, KF et al, "The Efficacy of Upper Cervical Chiropractic Care on Children and Adults with Cerebral Palsy: a preliminary report" *Chiropractic Pediatrics* 1994; 1(1):13-15.
14. Amalu WC, "Cortical blindness, cerebral palsy, epilepsy and recurring otitis media: A case study in chiropractic management." *Today's Chiropractic* May/June 1998 pp.16-25.
15. Roy RA, Boucher JP, Comtois AS. Consistency of cutaneous thermal scanning measures using prone and standing protocols: a pilot study. *J Manipulative Physiol Ther*. 2010 Mar-Apr;33(3):238-40.
16. Roy R, Boucher JP, Comtois AS. Validity of infrared thermal measurements of segmental paraspinal skin surface temperature. *J Manipulative Physiol Ther*. 2006 Feb;29(2):150-5.
17. Van den Noort JC, Scholtes VA, Becher JG, Harlaar J. Evaluation of the catch in spasticity assessment in children with cerebral palsy. *Arch Phys Med Rehabil*. 2010 Apr;91(4):615-23.
18. Valente AE. Improvement in a child with cerebral palsy undergoing subluxation based chiropractic care. *J Pediatr Matern & Fam Health*. 2009 Aug;3: 1-4.
19. Kent C. Models of vertebral subluxation: a review. *J Vert Sublux Res*: August 1996;1(1):1-7.

Instrumentation

A series of thermal and surface electromyography scans were performed throughout the course of care. Three thermal scans and four SEMG scans were performed.

Instrumentation revealed what appear to be consistent mid and upper cervical and thoracic spine hypertonicity and dysautonomia during the care intervals reported. The most significant area of hypertonicity is in the upper cervical region and the ongoing areas of hypertonicity are felt to be related to changes in muscle activity secondary to changes in cervical and thoracic spine due to the Harrington rod.

Follow-up Thermal scanning did not reveal a decrease in the dysautonomia in the cervical region from the initial scan although the pattern is dynamic. Follow-up Surface Electromyography scanning revealed a decrease in hypertonicity in the upper cervical and thoracic spine and a move toward a symmetrical pattern.

Figure 1 – Initial Thermal Scan

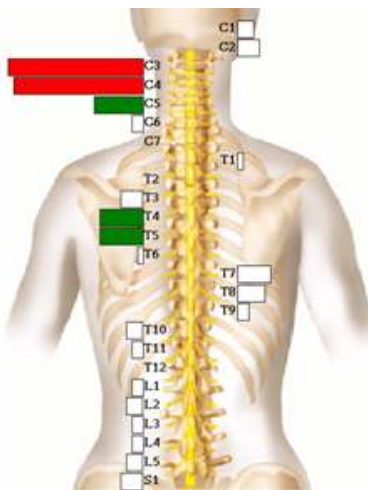


Figure 2 – Initial Surface Electromyography Scan

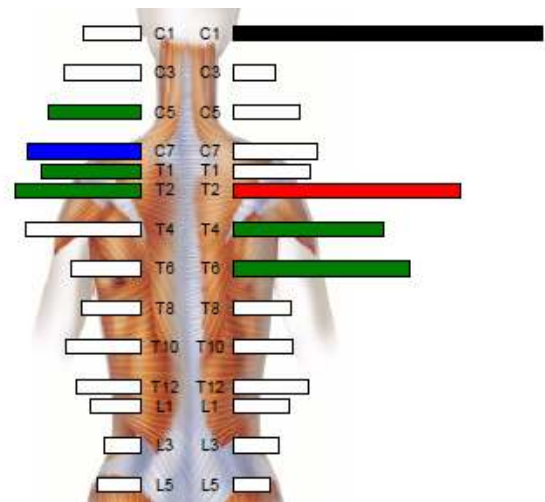


Figure 3 – Thermal Scan – 3 Months Later

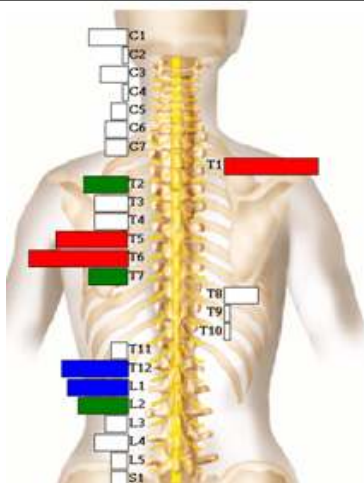
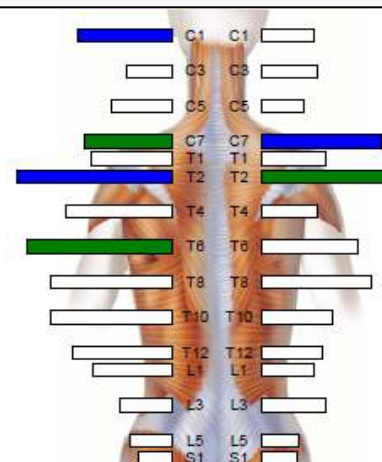
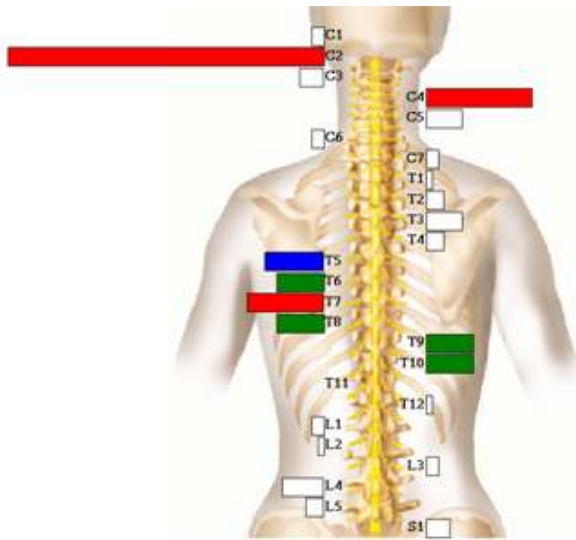


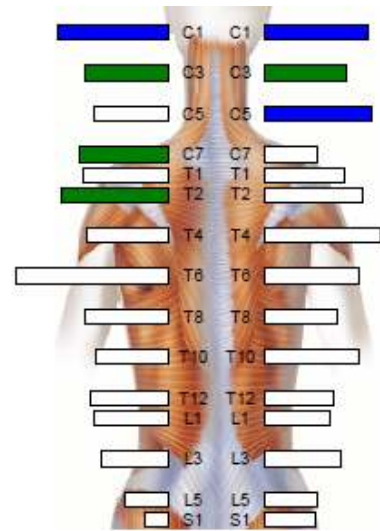
Figure 4 – Surface Electromyography Scan – 1 Month Later



**Figure 5 – Thermal Scan –
6 Months Later**



**Figure 6 – Electromyography Scan –
4 Months Later**



**Figure 7 – Electromyography Scan –
7 Months Later**

